

## **Extended hysterectomy (C<sub>1</sub> nerve-sparing dissection) in patients with invasive cancer of cervix**

V.S. Svintsitsky, L.I. Vorobjova, E.A. Stahovsky, T.V. Dermenzhy,  
N.F. Legerda, O.I. Iatsyna

*National Cancer Institute, Kyiv*

Surgical operations for cervical cancer are often accompanied by disruption of the normal functioning of urinary and reproductive systems. The main cause of these disorders is the surgical trauma of the pelvic autonomic nervous system innervating the urinary and reproductive systems' organs and that located in the immediate proximity from the area of surgical intervention. The aim of the study was to justify the use of extended hysterectomy (C<sub>1</sub> nerve-sparing dissection) in the clinical practice for treatment of patients with infiltrative cervical cancer and to evaluate the results of such treatment. 20 patients (mean age  $32,7 \pm 4,9$  years) with infiltrative cervical cancer underwent extended hysterectomy (C<sub>1</sub> nerve-sparing dissection) in gynecological oncology department of the National Cancer Institute in 2012. The first experience of extended hysterectomy for treatment of patients with infiltrative cervical cancer shows promising results in reducing the number of early postoperative complications in the urinary system. But for assessment the long-term results of treatment, the frequency of complications and quality of life further set of clinical data, randomized trials in specialized centers are required.

**Key words:** cervical cancer, extended hysterectomy (C<sub>1</sub> nerve-sparing dissection), cystomanometry, hypogastric nerve.

### ***Introduction***

Cancer of the cervix (CC) is the second most common cancer among women. According to WHO, about 500 000 new cases and 250 000 deaths are detected each year. In Ukraine in 2011 standardized incidence rate of CC equaled to 15.4 per 100 000 of female population, standardized mortality rate - 5.5. Current estimates indicate that 5344 women were diagnosed with CC and 2194 died from the disease in 2011 [1]. Recently incidence of CC among women before 40 years of age has been dramatically increasing [1,4].

Surgical treatment of invasive CC has more than 100 year's history. Currently, radical hysterectomy for stage IB-IIIB invasive CC, widely known as Wertheim operation, is the most common and frequently used approach worldwide. According to Piver, Rutledge and Smith, there are five classes of extended hysterectomy used in treating women with invasive CC (Piver M., Rutledge F., Smith J., 1974) [2, 8, 23]. Class I - extrafascial hysterectomy. Class II –

modified radical hysterectomy with removal of medial half of the cardinal and utero-sacral ligaments, class III - classical Meigs' radical hysterectomy [2, 8] with resection of utero-sacral, cardinal ligaments and upper half of the vagina and pelvic lymphadenectomy. This approach has become the standard technique for invasive cervical cancer in USA (Kenneth D., Hatch, Yao S. Fu, 1996) [8, 25]. Class IV – complete dissection of the ureter from the pubovesical ligament, the superior vesicle artery is sacrificed and upper three-quarters of the vagina removed. Class V include excision of distal ureter or bladder and reimplantation of ureter into the bladder (Fig. 1A,B).

An updated and a new, simple and anatomy based classification of hysterectomy for invasive CC was published by Querleu and Morrow in 2008 (Fig. 2) [13]:

**Type A. Extrafascial hysterectomy:**

- Lateral parametrium removed to the ureter;
- Ureter not tunneled;
- Anterior and posterior parametrium not removed;
- Vessels removed maximally close to the uterus;
- Vaginal resection is minimal without removal of the paracolpos.

**Type B. :**

- Ureter tunneled;
- Partial resection of utero-sacral and vesico-uterine ligaments;
- Resection of para-cervical ligament at the level of ureteral tunnel.

**Type C. :**

- Transection of lateral parametrium to the iliac vessels;
- Transection of vesico-uterine ligament at the bladder;
- Transection of utero-sacral ligament at the rectum;
- Ureter completely mobilized.

**Type C<sub>1</sub> (with autonomic nerve sparing/preservation):**

- Lateral parametrium – preservation of splanchnic nerves;
- Ventral parametrium – preservation of vesical branch of pelvis plexus;
- Dorsal parametrium – preservation of hypogastric nerve (Fig. 3).

In Fig.3 the levels of dissection of cardinal ligament in different types of hysterectomies are shown.

**Type C<sub>2</sub> (without autonomic nerve sparing/preservation):**

- Lateral parametrium - intersection of the splanchnic nerve;
- Ventral parametrium – intersection of vesical branch of pelvic plexus;

- Dorsal parametrium – all branches of hypogastric nerve are dissected.

In Fig.4 removed uterus after extended hysterectomy type C<sub>2</sub> is shown.

**Type D. Lateral parametrectomy:**

- The line of resection runs between internal obdurator internus muscle and lumbosacral plexus;
- Resection of internal iliac arteries and veins (Fig. 5A, B).

Surgical operations for CC are often accompanied by disorders of the normal functioning of the urinary and reproductive systems' organs. Frequency of urination disorders after surgery of the cervix is 78%, the frequency of sexual disorders - 90%. The main cause of these disorders is the surgical trauma of the pelvic autonomic nervous system innervating the urinary and reproductive systems' organs and are located in the immediate proximity from the area of surgical intervention (Levickis J., 1995; Hanna N.N., 2002) [3,9,10]. There are five main elements of the pelvic autonomic nervous system: the unpaired upper hypogastric plexus, the paired hypogastric nerves and the lower hypogastric plexus. The main symptoms of dysfunction of the urinary system are urinary retention or enuresis (Havenga K., 2000) [3, 11]. Dysfunctions of the woman's reproductive system are manifested by vaginal secretions and rhythmic contractions of vagina (Maurer C.A., 2001; Daniels I.R., 2006) [3, 12, 14].

Emerging advances in surgical techniques and other treatment modalities have led to development of the nerve-sparing operations - complex of surgical techniques preserving nerve structures of the pelvis (Moriya Y., 1995; Maas C.P., 2000) [5,6,16,17]. Numerous studies have confirmed that preservation of the pelvic autonomic nerves allows significantly reduce the number of postoperative urinary disorders. The high frequency of urinary functional disorders and urological complications after radical hysterectomy gave impetus to the development of nerve-sparing dissection technique. Functional preservation of pelvic innervation (primarily vascular) is possible in oncological patients by transvaginal hysterectomy with microsurgical dissection using laparoscopic technique. It is important to note that most of the researches regarding nerve-sparing operations in surgery of the cervix conducted by foreign authors [24, 26, 27]. In Ukraine, nerve-sparing technique has been recently developed in specialized medical centers. Despite advances in nerve-sparing techniques there is no adequate information regarding the indications depending on the stage of the tumor process, tumor localization and type of surgery.

**Materials and methods**

In order to study the effectiveness of nerve-sparing hysterectomy in the treatment of patients with infiltrative CC in gynecological oncology department of the National Cancer Institute the

indications, techniques, operation data, postoperative complications were evaluated.

Between 2012 and 2013 we performed laparoscopic radical hysterectomy for invasive CC in 40 patients. The mean age of patients was  $32,7 \pm 4,9$  years. According to the surgical technique patients were divided for two groups. Patients from group I (22 patients) underwent radical hysterectomy with preservation of the pelvic plexus and patients belonging to group II (20 patients) underwent standard radical hysterectomy without preservation of the pelvic plexus. Distribution of patients with infiltrative CC is given in Table 1.

Table 1. Distribution of patients with infiltrative cervical cancer

Clinical characteristics		Group of patients	
		I	II (control)
Age of patients, years	20–30	6	5
	31–40	10	11
	40–50	4	-
	51–60		4
Stage of cervical cancer	I B pT1bN0M0	13	8
	II A pT2aN0M0	7	12
Histological type	squamous cell carcinoma	12	19
	adenocarcinoma	2	1
Histological differentiation	GX	2	2
	G1	5	7
	G2	5	4
	G3	8	7

Statistical analysis was conducted using Statistica software version 5.0. For determination of significance of differences between groups Student t-test and Mann-Whitney U test were used.

The study protocol was approved by the Ethics Committee of National Cancer Institute, and an informed consent has been obtained from all patients.

## Results and discussion

Autonomic nerve sparing radical hysterectomy involves the separation of the lower hypogastric plexus, its uterine branch, resection only the uterine branch, which allows preserving the hypogastric nerve, pelvic splanchnic nerve and bladder branch of the lower hypogastric nerve plexus [18, 20]. However, until recently, the topographic anatomy of the lower hypogastric plexus consists of hypogastric nerve, pelvic splanchnic nerve, uterine branch and bladder branch has not been studied enough to perform nerve sparing surgery [18, 19].

Most often during the extended hysterectomy hypogastric nerve is injured under separation of the utero-sacral and recto-vaginal ligaments, pelvic splanchnic nerve is injured

under separation of the deep uterine vein of the cardinal ligament, and the bladder branch of the upper hypogastric plexus is injured under bandaging and separation of paracolpium [18,20]. Less radical surgery in which the incidence of such traumas is less compared to standard hysterectomy was developed by Japanese oncogynecologists in 1950 [18, 19]. Okabayashi proposed a method for extended hysterectomy, including the separation of the posterior leaf of the vesico-uterine ligament, which makes possible to separate only the uterine branch of lower hypogastric plexus, preserve innervation of the bladder, and avoid dysfunction of its contractile function in the postoperative period [18, 20]. Without stratification of the posterior leaf of vesico-uterine ligament it is difficult to visualize the lower hypogastric plexus, especially during standard Wertheim's operation. There are many published data regarding nerve sparing surgery using various surgical techniques. However, randomized trials comparing radical hysterectomy of C1 and C2 types were not carried out, which makes difficult to analyze published data on the dysfunction of the urinary and reproductive systems after surgical treatment [18, 20].

The uterus is innervated by part of the plexus hypogastricus inferior, which forms a so-called plexus of the Rhine or plexus uterovaginalis, s. uterinus magnus (the front part of the bottom of the plexus hypogastricus inferior).

Rhine plexus forms branches: 1) from the anterior roots of II, III and IV sacral nerves from which branch out 4-6 chains nn. erigentes (nn. erigentes referred to nn. pelvici). These chains connected with branches of the sacral ganglions of the sympathetic border trunk; 2) from the sacral and coccygeal part of the sympathetic border trunk; 3) through plexus hypogastricus inferior, from the lumbar sympathetic trunks, as well as X, XI, XII thoracic nerves, 4) from the plexus haemorrhoidales inferior, extending from the plexus mesogastricus inferior, by which functional relationship is established between genital apparatus and the rectum (Fig. 6).

Pelvic plexus contains mainly sympathetic chain, and chain nn. pelvici and therefore is a mixed plexus. Thus, the uterus, vagina, bladder and rectum are innervated by the motor and sensory nerves of sympathetic and parasympathetic autonomic nervous system. Sympathetic chain extending from Th11-L2 forms the upper hypogastric plexus. Parasympathetic chain extending from S2-S4 to the walls of the pelvis forms the pelvic splanchnic nerve. These chains merge and form inferior hypogastric plexus, the branches of which innervate the uterus and bladder.

Topographic anatomy of the inferior hypogastric plexus, including the hypogastric nerve, pelvic splanchnic nerve, bladder branch, uterine branch of this plexus, is quite complex and it is not easy to be visualized during the radical hysterectomy. In order to preserve the pelvic splanchnic nerve, it is necessary to visualize the inferior hypogastric plexus, this requires a thorough knowledge of the anatomy of the pelvis and the parametrial area (topography of the

deep veins of the uterus) [18, 20, 21]. Moreover it is also very important to have knowledge of the anatomy of the vesico-uterine ligament, especially its posterior leaf.

The anatomy of the vesico-uterine ligament (anterior/posterior leaf) is given on Fig. 7,8.

In the anterior leaf of vesico-uterine ligament are visualized: uterine artery, superficial veins of the uterus, ureter branch of the uterine artery, superficial bladder veins flowing into superficial uterine veins, cervico-vesical vessels. Division of blood vessels from the connective tissue of anterior leaf of the vesico-uterine ligament is presented. In the posterior leaf of vesico-uterine ligaments two major bladder veins flowing into the deep veins of the uterus are usually localized (Fig. 8). Dissection of these veins gives access to the inferior hypogastric plexus, which allows separating only uterine branch. After isolation of paracolpium T-shaped hypogastric nerve plane is visualized and only the uterine branch is cut-ended, vaginal cuff is released, the uterus is removed (Fig. 9A, B).

The schematic drawings present extended hysterectomy (C1 nerve-sparing dissection) in patients with invasive CC, from Textbook of gynaecological oncology, 2012 (Ayhan A., Reed N., Gultekin M., Dursun P.).

Stages of nerve-sparing hysterectomy, which was held in gynecological oncology department of the National Cancer Institute, are presented below:

**Division of uterine branches from the inferior hypogastric plexus.** Below hypogastric nerve, branch of the inferior hypogastric plexus is separated from the blood vessels of the paracolpium (Figure 10 A, B). Division is between bladder branch and blood vessels of the paracolpium in the connective tissue between the pelvic nerve plane and the cervix/upper part of the vagina at the hypogastric nerve on the ventral side and deep uterine veins on the dorsal side. From the side of the uterus, uterine branch of the inferior hypogastric plexus clamped, cut off after a sensation resembling a gap stretched string. Dissection of the recto-vaginal ligament separates the blood vessels of paracolpium from the T-shaped nerve plane. After division of the recto-vaginal ligament of the upper part of the vagina, bladder branch of the inferior hypogastric plexus, forming a T-shaped nerve plane, dissection and ligating of blood vessels of paracolpium distally along the vagina below the level of cervix lesion is performed (Fig. 11,12).

***Formation of protective wall for juxtavesical portion of the ureter by the walls of the rectum and bladder.***

The inflection of the ureter is one of the most serious post-operative problems leading to hydroureter and hydronephrosis with possible dysfunction of the kidneys. To prevent the immersion of juxtavesical part of ureter into the pelvis and its bend two seams are applied laterally from the ureter between the outer wall of the rectum and the bladder.

The function of the lower urinary tract after radical hysterectomy with preservation of the pelvic plexus in patients with infiltrative CC has been studied using cystomanometry on urodynamic rack URO-PRO by the standard method.

In the early postoperative period, in all patients contractile function of the bladder has been assessed.

Cystomanometry – registration of changes in intravesical pressure in the process of its filling and urination. Cystomanometry reflects: 1) sensor characteristics of bladder; 2) adaptive properties of the detrusor (its ability to maintain a low intravesical pressure during filling and lack of unbraked contractions; 3) dynamic of the intravesical pressure during urination [7, 15, 22].

Extensibility of the bladder was considered as a change in detrusor pressure at a certain change in the filling volume and was calculated according to the formula:  $K=\Delta V/\Delta P$ , where K – extensibility of the bladder wall (in ml / cm wat.columnn),  $\Delta V$  — volume change,  $\Delta P$  – detrusor pressure change at the time of change the volume. Under preservation of the pelvic nerve plexus extensibility of the bladder wall was more than 10 mL / cm of water column with up to 100 mL volume and more than 25 mL / cm of water column with up to 500 ml volume (Fig. 13,14).

After nerve-sparing hysterectomy in 80% of patients of group I contractile function of the bladder recovered completely in 2-3 days after surgery, while in the control group - only in 20% of patients. In 7 days after the radical hysterectomy in all patients of group I normal function of the lower urinary tract was completely restored while in patients of group II recovery period lasted from 7 to 21 days (Table 2).

Conducted study of extended hysterectomy (C1 nerve-sparing dissection) for infiltrative CC shows promising results in reducing the number of early postoperative complications in the urinary system. However to assess the long-term results of treatment, the frequency of complications and quality of life of patients further set of clinical data, randomized trials in specialized centers are required.

Table 2. Restore of function of the lower urinary tract in patients with infiltrative cervical cancer.

Restore of function of the lower urinary tract, days	I group of patients	II group (control) of patients
1-3	16	-3
4-7	4	-1
8-14	-	7
15-21	-	9

## Conclusion

1. Radical nerve-sparing hysterectomy in patients with infiltrative cervical cancer allows preserving the function of the lower urinary tract in the postoperative period: the indicators of cystomanometry in these patients 60% higher than in patients of the control group.
2. Radical nerve-sparing hysterectomy should not be performed in patients with the IIB FIGO stage of the cervical cancer, since the location of the lower hypogastric plexus is very close to the site of the tumor lesion.

## References

1. Cancer in Ukraine, 2010–2011. Morbidity, mortality, indicators of cancer care service (2012) Bulletin of National Cancer Registry of Ukraine, 13: 124 (in Ukrainian).
2. Werner P., Zederl Y. (1960) Wertheim's radical surgery for cancer of cervix. Medicine, Moskow: 74p. (in Russian).
3. Belyaev A.M., Manikhas G.M., Domanski A.A., Bratov O.Z. (2010) The ability to perform nerve-sparing surgery in different categories of patients with rectal cancer. Biomedical Journal. Medline.ru, 11: 597-610 (in Russian).
4. Vorobjova L.I. (2010) Current approaches to diagnostic, treatment and prevention of cervical cancer. Female doctor 5: 18–21 (in Ukrainian).
6. Belyaev A.M., Domanski A.A., Zakharenko A.A. et al. (2011) Results of nerve-sparing operation in surgery of complicated rectal cancer. Biomedical Journal. Medline.ru, 12: 495-510 (in Russian).
7. Yatsyna O.I., Stakhovsky E.O., Vitruk Y.V., Chernienko Y.L. Patent № 58393, Ukraine, MPK6 A61V5/00. Method for determining the storage function of orthotopic ileal bladder. Number 201011467, appl. 27.09.2010, publ. 11.04.11, Bull. Number 7: P. 27 (in Ukrainian).
8. Kuznetsov V.V., Lebedev A.I., Morkhov K.Y., Gritsay A.N. (2002) Surgery of invasive cancer of the cervix. Practical Oncology, 3 (3): 178-182 (in Russian).
9. Levickis J. et al. (1995) Bladder and erectile dysfunction before and after rectal surgery for cancer. Br. J. Urol., 76: 752–756.



10. Hanna N.N., Guillem J., Dosoretz A. et al. (2002) Intraoperative parasympathetic nerve stimulation with tumescence monitoring during total mesorectal excision for rectal cancer. *J. Am. Coll. Surg.*, 195: 506–512.
11. Havenga K., Maas C.P., DeRuiter M.C. et al. (2000) Avoiding long-term disturbance to bladder and sexual function in pelvic surgery, particularly with rectal cancer. *Semin. Surg. Oncol.*, 18: 235–243.
12. Maurer C.A., Z'graggen K., Renzulli P. et al. (2001) Total mesorectal excision preserves male genital function compared with conventional rectal cancer surgery. *Brit. J. Surg.*, 88: 1501–1505.
13. Querleu D., Morrow C.P. (2008) Classification of radical hysterectomy. *Lancet Oncol.*, 9: 297–303.
14. Daniels I.R., Woodward S., Taylor F.G. et al. (2006) Female urogenital dysfunction following total mesorectal excision for rectal cancer. *World J. Surg. Oncol.*, 4: 6.
15. Lowery A.E., Holland J.C. (2011) Screening cancer patients for distress guidelines for routine implementation. *Community oncology*, 8(11): 502–505.
16. Moriya Y., Sugihara K., Akasu T. et al. (1995) Nerve-sparing surgery with lateral node dissection for advanced lower rectal cancer. *Eur. J. Cancer*, 31A: 1229–1232
17. Maas C.P., Moriya Y., Steup W.H. et al. (2000) A prospective study on radical and nerve-preserving surgery for rectal cancer in the Netherlands. *Eur. J. Surg. Oncol.*, 26(8): 751–757.
18. Ayhan A., Reed N., Gultekin M., Dursun P. (2012) Textbook of gynaecological oncology, 106: 635–639.
19. Dursun P., Ayhan A., Kuscü E. (2009) Nerve-sparing radical hysterectomy for cervical carcinoma. *Crit. Rev. Oncol. Hematol.*, 70(3): 195–205.
20. Fujii S., Takakura K., Matsumura N. et al. (2007) Anatomic identification and functional outcomes of the nerve sparing Okabayashi radical hysterectomy. *Gynecol. Oncol.*, 107: 4–13.
21. Fujii S. (2008) Anatomic identification of nerve-sparing radical hysterectomy: A step-by-step procedure. *Gynecol. Oncol.*, 111: S33–S41.
22. Chin-Peuckert L., Pippi Salle J.L. (2001) A modified biofeedback program for children with detrusor-sphincter dyssynergia: 5-year experience. *J. Urol.*, 166: 1470–1475.
23. Piver M.S., Rutledge F., Smith J.P. (1974) Five classes of extended hysterectomy for women with cervical cancer. *Obstet. Gynecol.*, 44: 265–272.
24. Li B., Zhang R., Wu L.Y. (2008) A prospective study on nerve-sparing radical hysterectomy in patients with cervical cancer. *Chin. J. Gynecol. Oncol.*, 43: 606–610.

25. Kenneth D., Hatch Yao S. Fu (1996) Cancer cervical and vaginal. Novak editor. Gynecology. 12-th ed. Williams Wilkins, New York: 1111–1144.
26. Raspagliesi F., Ditto A., Fontanelli R. et al. (2004) Nerve-sparing radical hysterectomy: a surgical technique for preserving the autonomic hypogastric nerve. Gynecol. Oncol., 93: 307–314.
27. Sakuragi N., Todo Y., Kudo M. et al. (2005) A systematic nerve-sparing radical hysterectomy technique in invasive cervical cancer for preserving postsurgical bladder function. Int. J. Gynecol. Cancer, 15: 389–397.

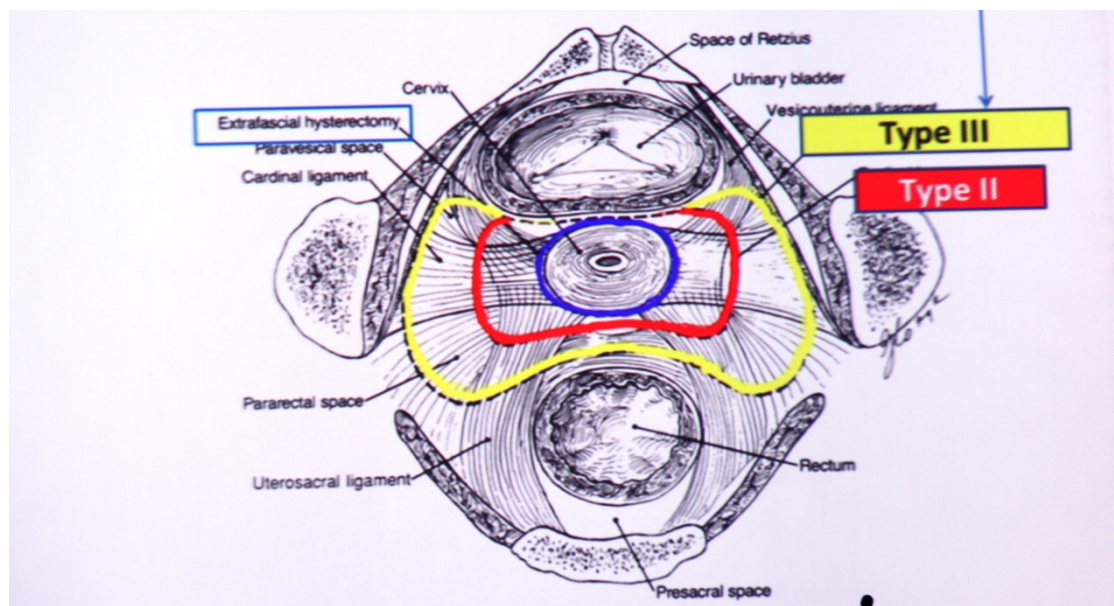


Figure 1A. Piver M., Ratledge F., Smith J. classification (horizontal section of the pelvis).

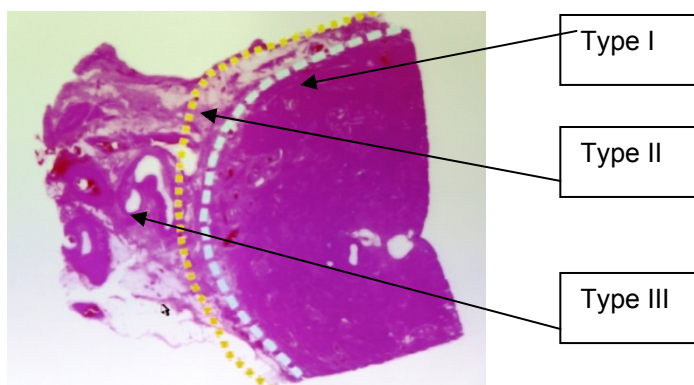


Figure 1B. Piver M., Ratledge F., Smith J. classification (hystology).

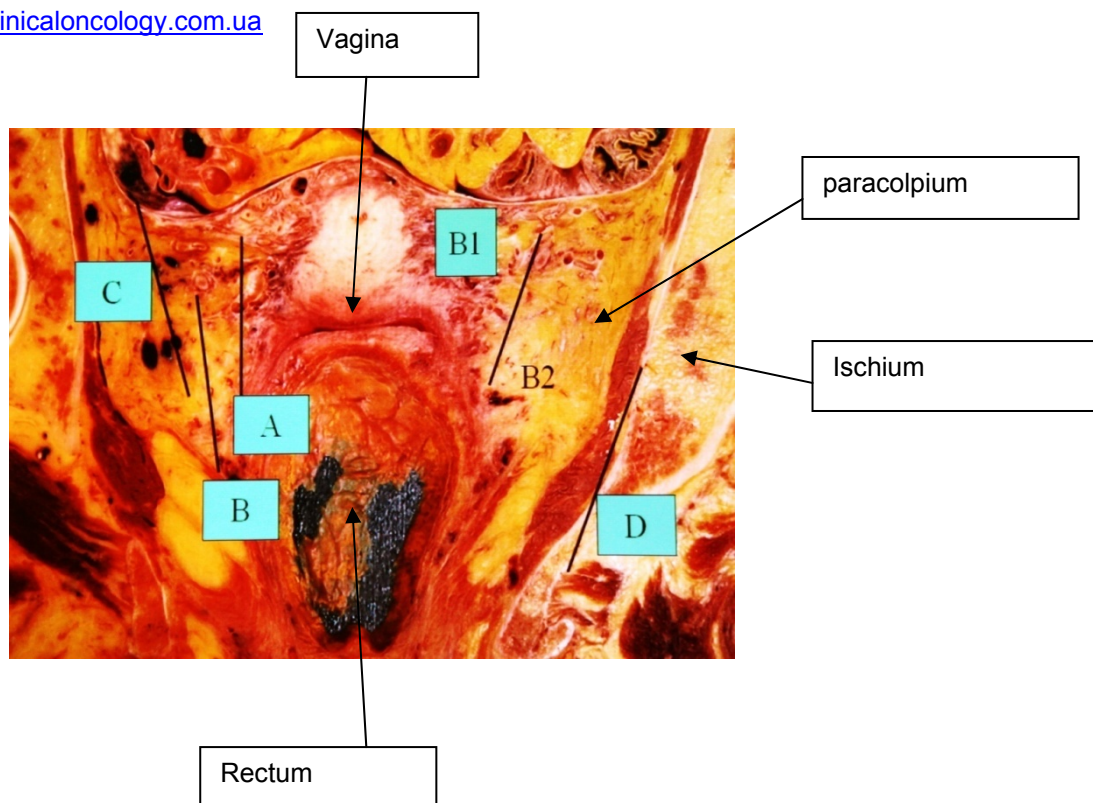


Рис 2. D. Querleu, C.P. Morrow classification (horizontal section of the pelvis).

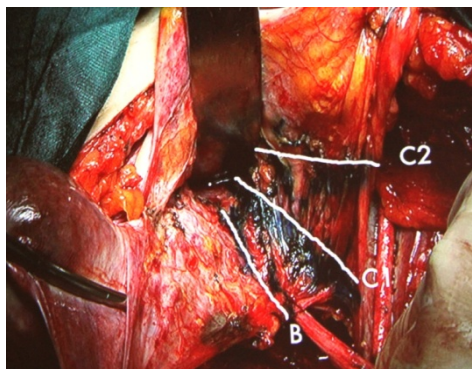


Figure 3. Dissection levels of cardinal ligament in different types of hysterectomy.

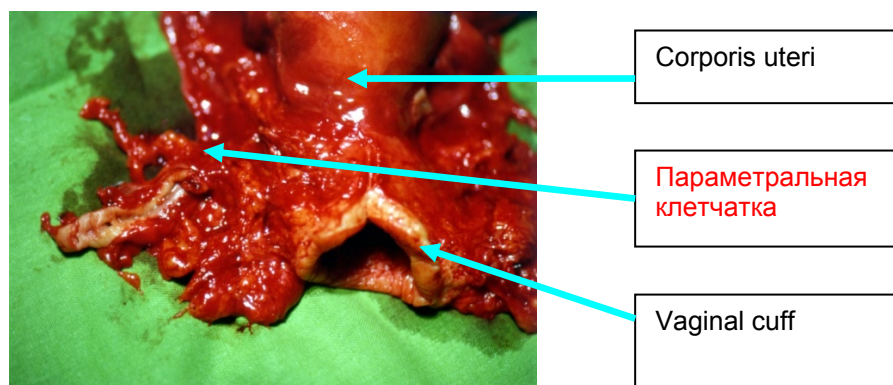
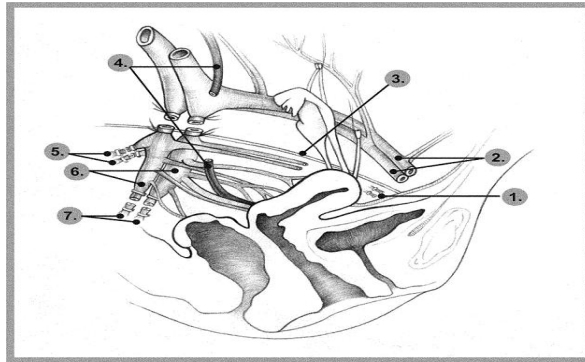
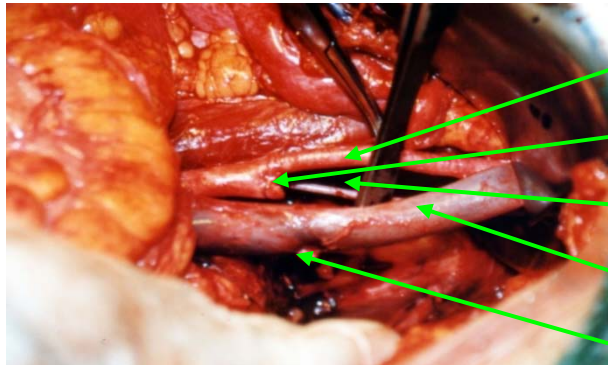


Figure 4. Removed uterus after C<sub>2</sub> extended hysterectomy.



1. Obturator vessels.
2. External iliac vessels
3. Obturator nerve.
4. Ureter.
5. Superior gluteal vessels.
6. Hypogastric vessels.
7. Inferior gluteal vessels.



External iliac artery

Stump of the internal iliac artery

Obturator nerve

External iliac vein

Stump of the internal iliac vein

Figure 5A. Lateral parametrectomy



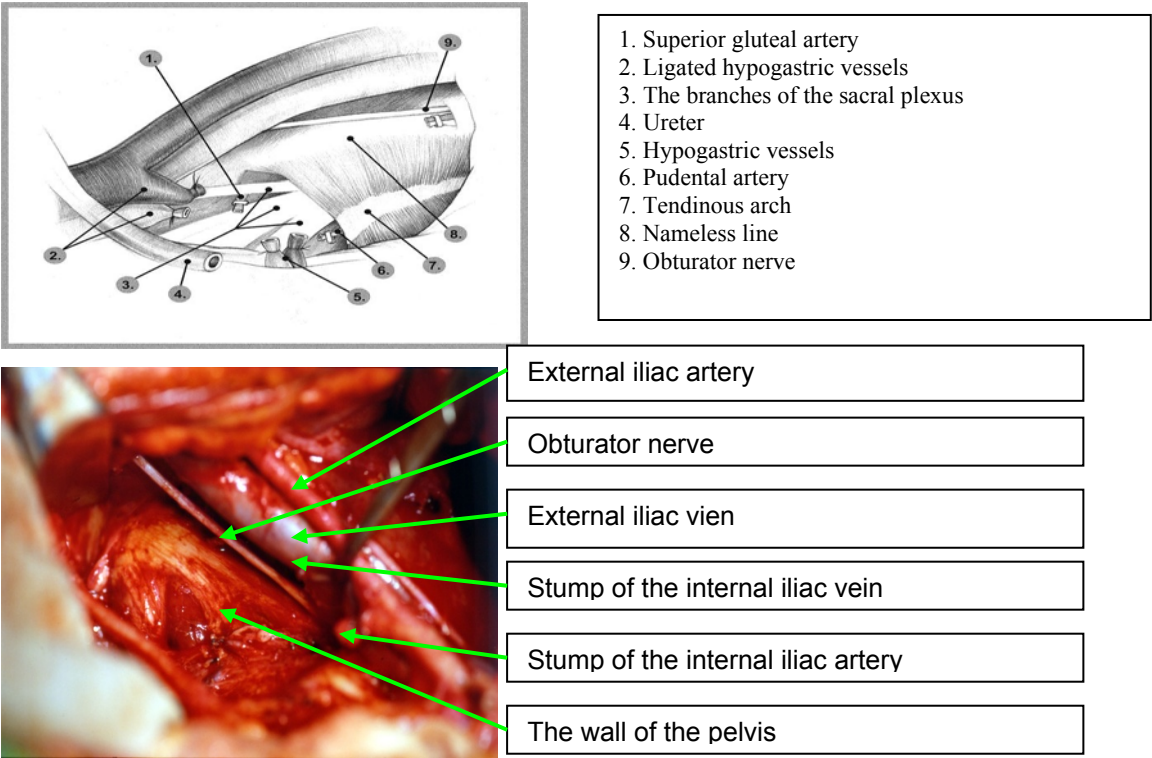


Figure 5B. Lateral parametrectomy



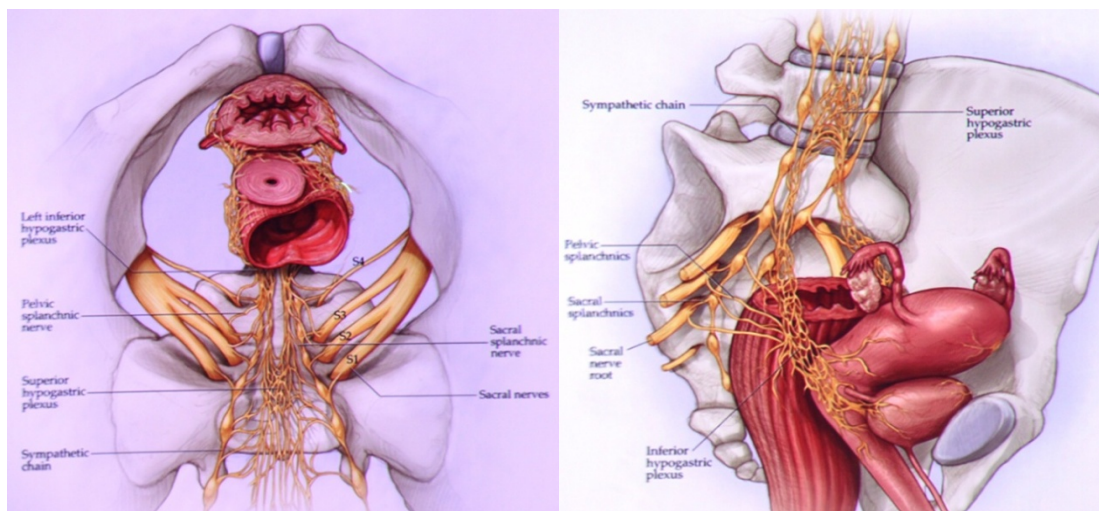


Figure 6. Schematic representation of the anatomy of the lower hypogastric plexus

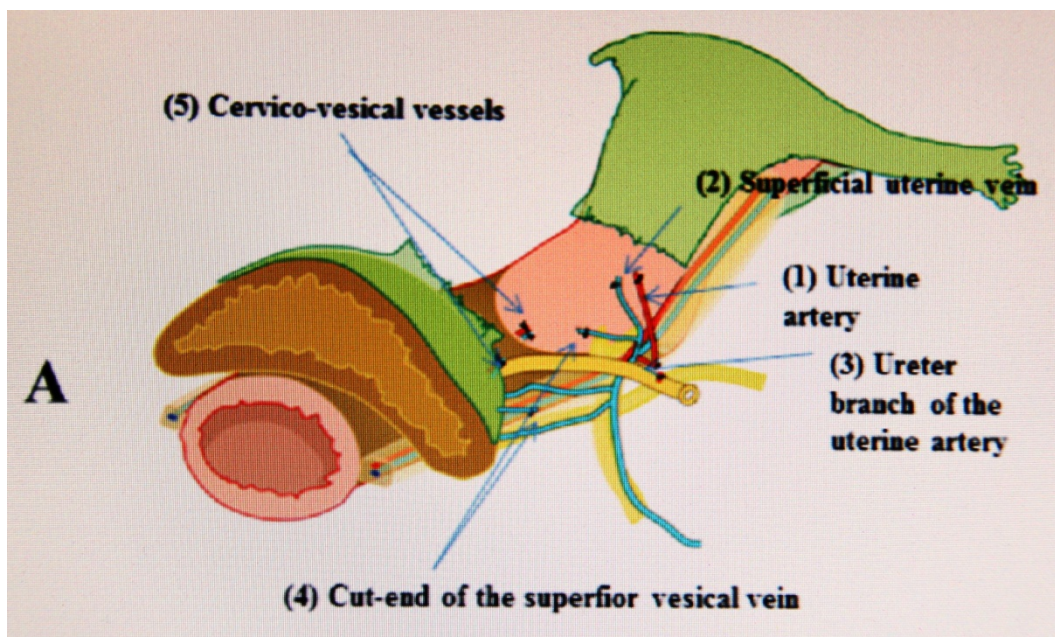


Figure 7. Anterior leaf of the vesico-uterine ligament

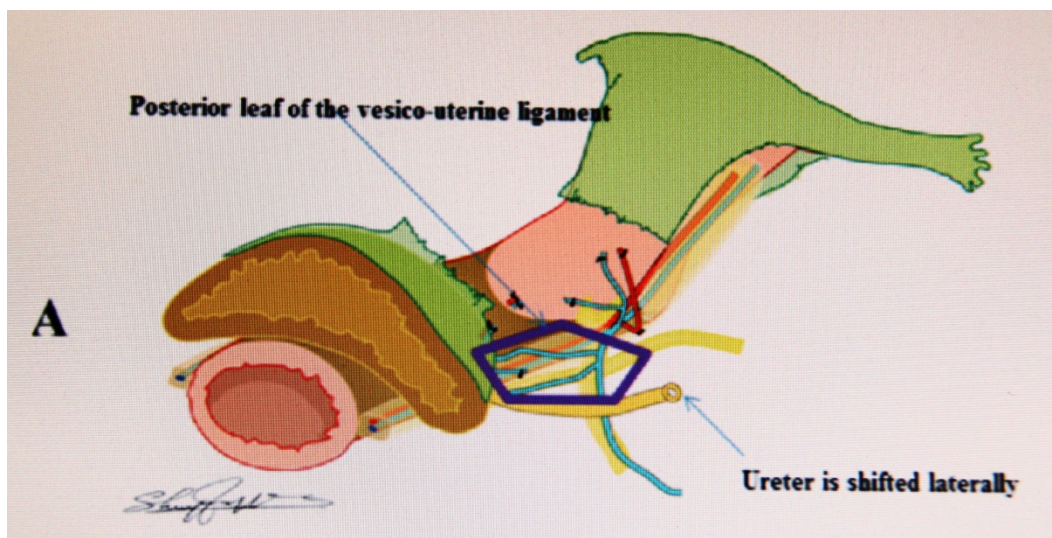


Figure 8. Posterior leaf of the vesico-uterine ligament. Separation of vesical viens flowing into deep uterus viens

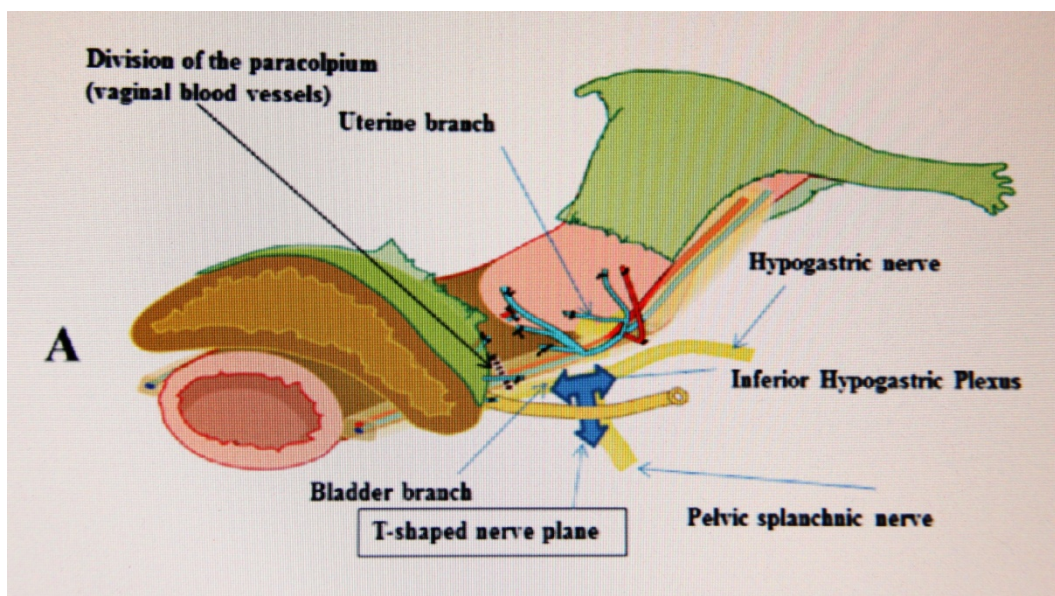


Figure 9A. T-shaped nerve plane



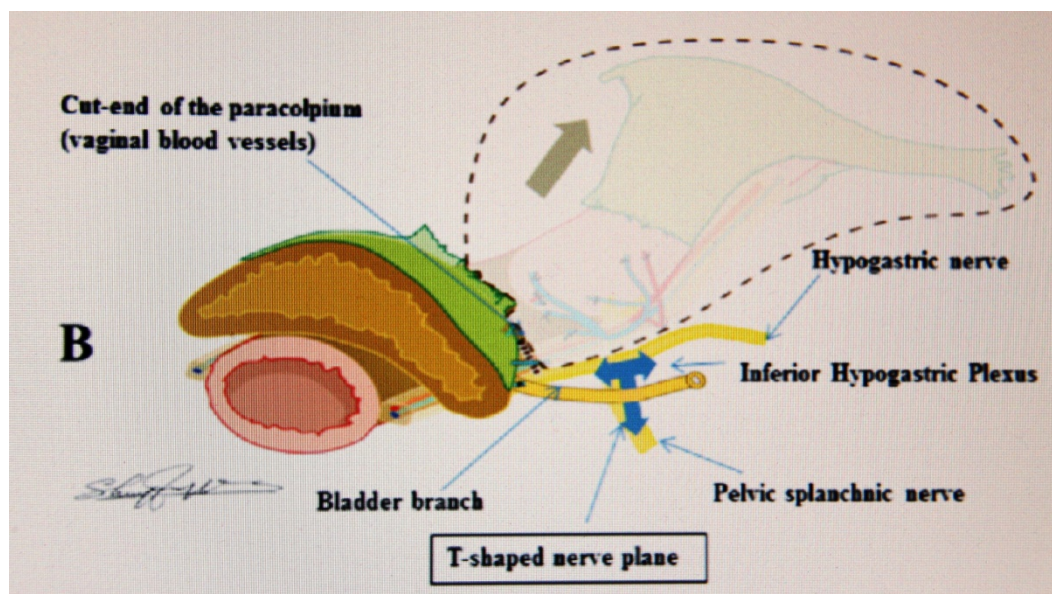


Figure 9B. T-shaped nerve plane and view after hysterectomy

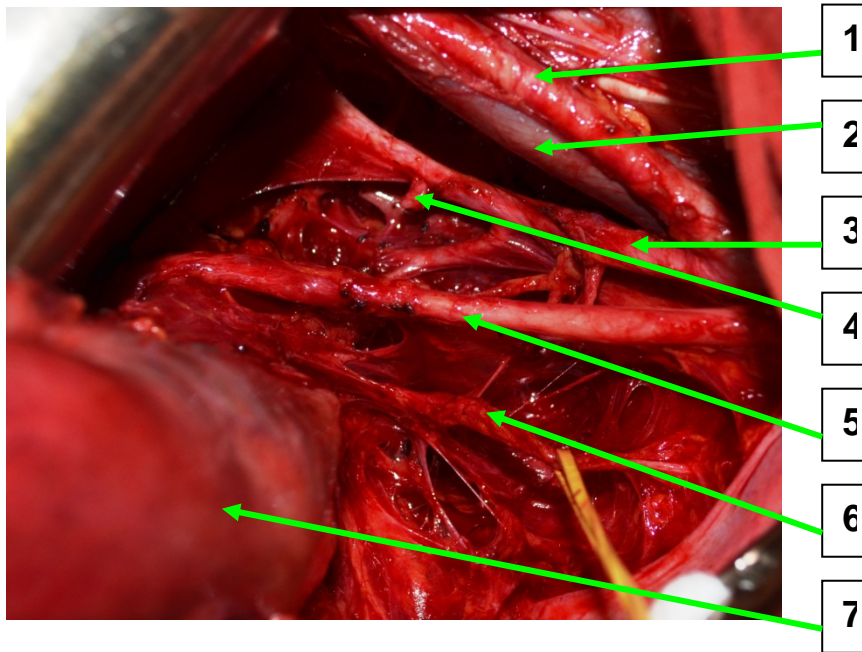


Figure 10A. Nerve-sparing operation for infiltrative cervical cancer (1 - external iliac artery, 2 - external iliac vein, 3 - internal iliac artery, 4 - stump of the uterine artery, 5 - ureter, 6 - pelvic plexus, 7 - uterus)

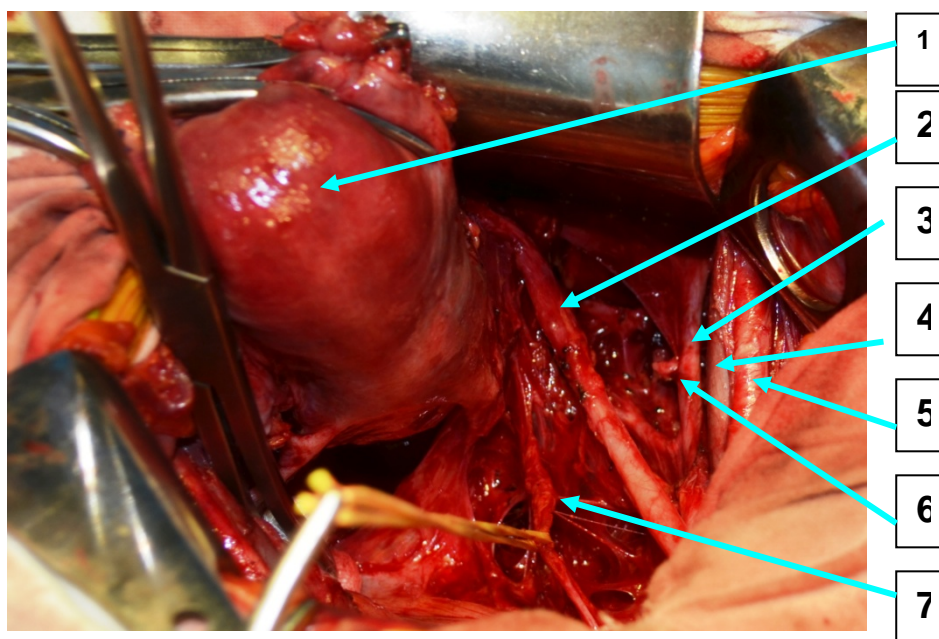


Figure 10B. Nerve-sparing operation for infiltrative cervical cancer (1 - uterus. 2 - ureter, 3 - internal iliac artery, 4 - external iliac vein, 5 - external iliac artery, 6 - uterine stump artery, 7 - hypogastric pelvic plexus)

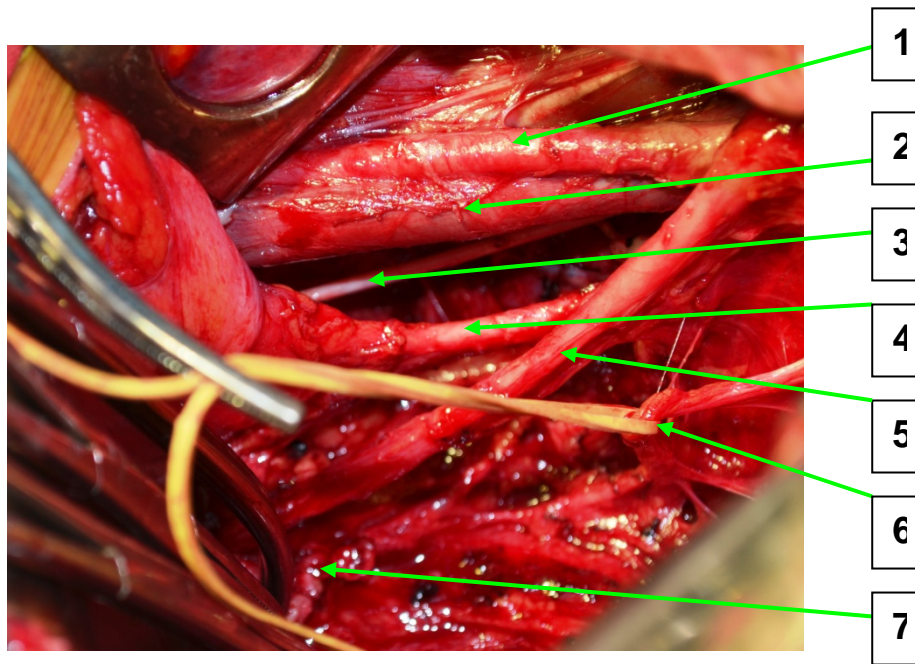


Figure 11. Nerve-sparing operation for infiltrative cervical cancer (1 – external iliac artery; 2 – external iliac artery; 3 – obturator nerve; 4 – vesicular artery; 5 – ureter; 6 – pelvic plexus; 7 – vaginal stump)



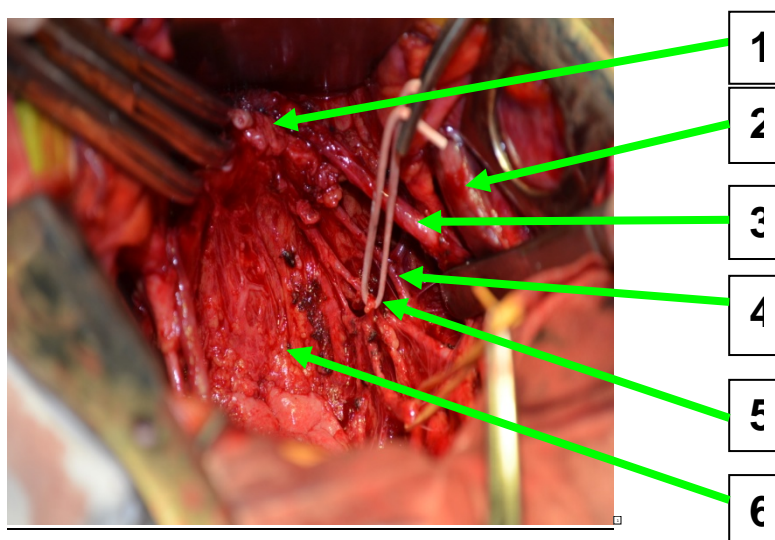
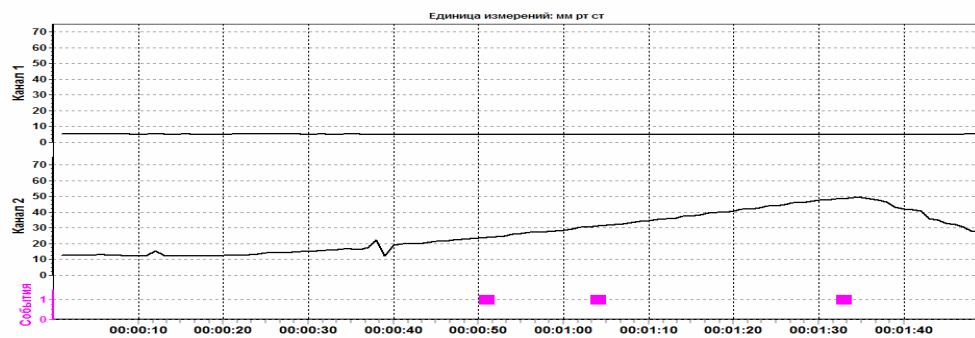


Figure 12. Nerve-sparing operation for infiltrative cervical cancer (1 – vaginal stump, 2 - external iliac artery, 3 – ureter, 4 - vesicular artery, 5 – pelvic plexus, 6 - rectum)



P1=22 millimeter mercury.; P2=30 millimeter mercury.;  $\Delta P=8$  millimeter mercury.;  
 $\Delta V=403$  ml;

K=37 ml/cm water column.

P1 – pressure under filling of bladder;

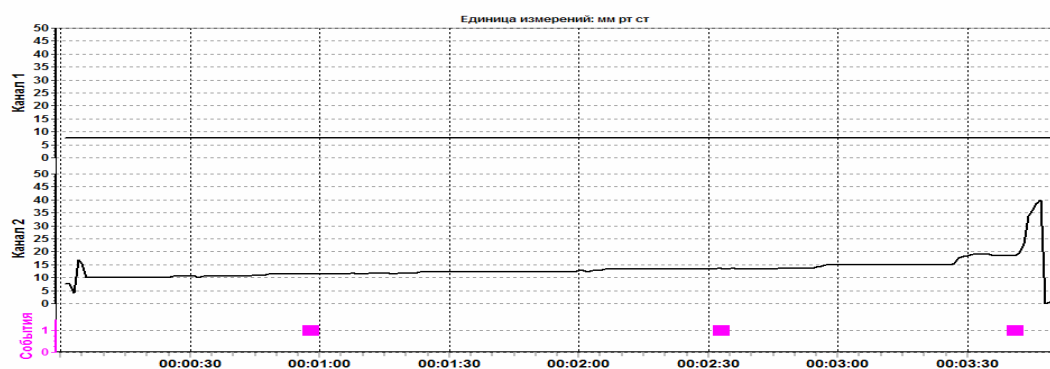
P2 – pressure of the first urge;

$\Delta P$  – pressure difference;

$\Delta V$  – volume difference;

K – extensibility coefficient of the bladder wall.

Figure 13. Cystomanometry of cervical cancer patient after radical hysterectomy with preservation of pelvic plexus.



P1=10 millimeter mercury; P2=14 millimeter mercury;  $\Delta P=4$  millimeter mercury;  
 $\Delta V=125$  ml;  $K=23,14$  ml/cm water column.

Figure 14. Cystomanometry of cervical cancer patient after radical hysterectomy without preservation of pelvic plexus.